

Ultrasonography of the wrist - a step-by-step approach to study protocols and normal findings

Poster No.: C-1779
Congress: ECR 2016
Type: Educational Exhibit
Authors: R. R. Domingues Madaleno, A. P. Pissarra, I. Abreu, A. Canelas, L. Curvo Semedo, F. Caseiro Alves; Coimbra/PT
Keywords: Education and training, Education, Diagnostic procedure, Ultrasound, Musculoskeletal joint, Extremities, Bones
DOI: 10.1594/ecr2016/C-1779

Any information contained in this pdf file is automatically generated from digital material submitted to EPOS by third parties in the form of scientific presentations. References to any names, marks, products, or services of third parties or hypertext links to third-party sites or information are provided solely as a convenience to you and do not in any way constitute or imply ECR's endorsement, sponsorship or recommendation of the third party, information, product or service. ECR is not responsible for the content of these pages and does not make any representations regarding the content or accuracy of material in this file.

As per copyright regulations, any unauthorised use of the material or parts thereof as well as commercial reproduction or multiple distribution by any traditional or electronically based reproduction/publication method is strictly prohibited.

You agree to defend, indemnify, and hold ECR harmless from and against any and all claims, damages, costs, and expenses, including attorneys' fees, arising from or related to your use of these pages.

Please note: Links to movies, ppt slideshows and any other multimedia files are not available in the pdf version of presentations.

www.myESR.org

Learning objectives

To present a review of the evaluation protocols of the wrist using ultrasonography, illustrated with didactic schemes and videos.

To describe the normal anatomy of the articular structures of the wrist.

Background

The ultrasonography of the wrist has a pivotal role in its imaging evaluation. It offers the advantages of good spatial resolution, real time evaluation, contralateral comparison and guidance in joint interventions.

Ultrasonography also allows an evaluation in different positions of the wrist, as well as static and dynamic scanning, thus yielding a good accuracy in the depiction of the main pathology of this joint.

Wrist is usually approached through its dorsal and palmar segments (Fig. 1).

Images for this section:

Dorsal segment	First compartment	Abductor pollicis longus (APL) tendon Extensor pollicis brevis (EPB) tendon Radial artery and nerve
	Second compartment	Extensor carpi radialis longus (ECRL) tendon Extensor carpi radialis brevis (ECRB) tendon
	Third compartment	Extensor pollicis longus (EPL) tendon
	Fourth compartment	Extensor digitorum communis (EDC) tendons Extensor indicis proprius (EIP) tendons
	Fifth compartment	Extensor digiti minimi (EDM) tendon
	Six compartment	Extensor carpi ulnaris (ECU) tendon
	Scapholunate ligament	
	Lunatriquetal ligament	
	Triangular fibrocartilage	
Ventral segment	Proximal carpal tunnel	Flexor retinaculum Flexor digitorum superficialis (FDS) and profundus (FDP) tendons Flexor pollicis longus (FPL) tendon Flexor carpi radialis (FCR) tendon
	Distal carpal tunnel	Median nerve
	Guyon tunnel	Ulnar nerve, artery and vein

Fig. 1: Checklist of ultrasonography of the wrist.

© Radiology Department, Coimbra University Hospital - Coimbra/PT

Findings and procedure details

TECHNIQUE

For the evaluation of the wrist, the patient sits in front of the examiner with the elbow and the wrist resting over the examination table.

A highfrequency linear transducer (12-17 MHz) should be used.

Wrist is divided in dorsal and palmar segments. Dorsal segment is the compartment where the extensor tendons are located and is divided in six compartments. Ventral segment is the compartment of the carpal and Guyon tunnels.

DORSAL SEGMENT

For the initial evaluation of the dorsal segment of the wrist, the transducer is placed in a transverse plane over the pronate wrist. For dynamic scanning of the extensor tendons, the hand can be placed over a pillow, a towel or a gel tube with finger hanging outside its edge to allow easy movements of the fingers and a passive flexion of the radiocarpal joint (Fig. 2). Identification of the individual tendons in each compartment is allowed by its location and its behavior at dynamic examination.

FIRST COMPARTMENT

In the first segment one can find the abductor pollicis longus (APL) and extensor pollicis brevis (EPB) tendons. For their assessment, the wrist is placed halfway between pronation and supination, and the transducer over the radial styloid process. APL tendon appears as a rounded hyperechoic structure in ventral position and EPB tendon in a dorsal position (Fig. 3). The extensor retinaculum appears as a thin hypoechoic line that passes over the tendon. It can have a vertical septum that divides the first compartment. In the assessment of the distal APL sometimes it's possible to see APL accessory tendon. In this position, the radial artery and nerve also appear in a ventral position, with the former more deep and the second more superficial.

SECOND COMPARTMENT

In the second compartment it's possible to find the extensor carpi radialis longus (ECRL) and the extensor carpi radialis brevis (ECRB) tendons. They are examined with the palms of the hand down and with the probe in the transverse plane over the radial styloid (Fig.

4). If the transducer sweeps proximally, it is possible to identify the tendons of the first compartment crossing superficially from the ulnar to the radial side (Fig. 5).

THIRD COMPARTMENT

In the third compartment one can see the extensor pollicis longus (EPL) tendon. For its assessment, the probe is placed over the Lister's tubercle, and the second compartment will appear in the radial side and the third compartment in the ulnar side (Fig. 6). If the EPL tendon is followed to its insertion, it will cross the second compartment tendons superficially (Fig. 7).

FOURTH AND FIFTH COMPARTMENTS

In the fourth compartment it's possible to find the extensor digitorum communis (EDC) and extensor indicis proprius (EIP) tendons. The transducer should be placed in mid dorsal wrist, and the tendons appears in the ulnar side of the EPL tendon (third compartment) (Fig. 8).

In the fifth compartment there is the extensor digiti minimi (EDM) tendon, that it is located between radius and ulna, in the ulnar side of the fourth compartment (Fig. 8).

Dynamic scanning of these compartments could be useful to differentiate the EDC, EIP and EDM tendons (Fig. 9).

SIXTH COMPARTMENT

In the sixth compartment it's possible to see the extensor carpi ulnaris (ECU) tendon. The wrist is placed in radial deviation and the transducer over the styloid process of the ulna. The ECU will appear between the head and styloid process of the ulna (Fig. 10).

LIGAMENTS OF THE WRIST

The ligaments of the wrist can also be assessed by ultrasonography, at least partially.

The probe should be placed distally to the Lister's tubercle, in the transverse plane. Scapholunate ligament appears as a triangular fibrillar structure between lunate and scaphoid (Fig. 11). Ulnar deviation of the wrist could help to assess this ligament.

If the probe is swept to the ulnar side, the lunatutriquetral ligament appears between triquetrum and lunate (Fig. 12).

With the wrist in radial deviation and the transducer in a longitudinal plane, one can find the triangular fibrocartilage distally to the styloid of the ulna. The triangular fibrocartilage

appears deep to the extensor carpi ulnaris tendon in the sixth compartment, as an echogenic inverted triangular structure.

VENTRAL SEGMENT

For the examination of the ventral segment of the wrist, the transducer is placed in a transverse plane over the supinate wrist.

PROXIMAL CARPAL TUNNEL

For assessment of the proximal carpal tunnel, the transducer is placed transversally, over the scaphoid tubercle and the pisiform, on radial and ulnar side respectively.

The flexor retinaculum appears as a hypoechogenic band that crosses over the carpus, and below which are the flexors tendons and the median nerve.

The flexors tendons are divided in four from flexor digitorum superficialis, four from flexor digitorum profundus and flexor pollicis longus tendon that appear in radial side (Fig. 13). Dynamic scanning with finger flexion could be useful for the identification of these tendons and their normal motion. Sweeping the probe to the radial side, flexor carpi radialis appears over scaphoid.

DISTAL CARPAL TUNNEL

For the assessment of the distal carpal tunnel, the transducer is swept distally to a transverse plane with the trapezium tubercle on the radial side and the hamate hook on the ulnar side. The flexion of the wrist could be useful to better evaluate the carpal tunnel.

The median nerve appears as an elliptic structures that often courses just deep to the flexor retinaculum, parallel to the second and third flexor tendons (Fig. 14). For the proper examination of the median nerve, the probe should be shifted distally in the carpal tunnel. The examiner should be aware to the possible anatomic variants, like persistent median artery or a bifid proximal median nerve.

GUYON TUNNEL

In the medial side of the supine wrist, with the transducer in a transverse plane, it is possible to examine the Guyon tunnel with ulnar nerve, artery and vein. After identification of the pisiform bone, the artery appears as a round, pulsatile hypoechoic structure in radial side and the ulnar nerve appears between the pisiform and the ulnar artery as a small structure with internal hypoechoic fascicles (Fig. 13). If the ulnar nerve is followed

distally, it's possible to identify its two branches, the superficial sensory and the deep motor branches.

Images for this section:

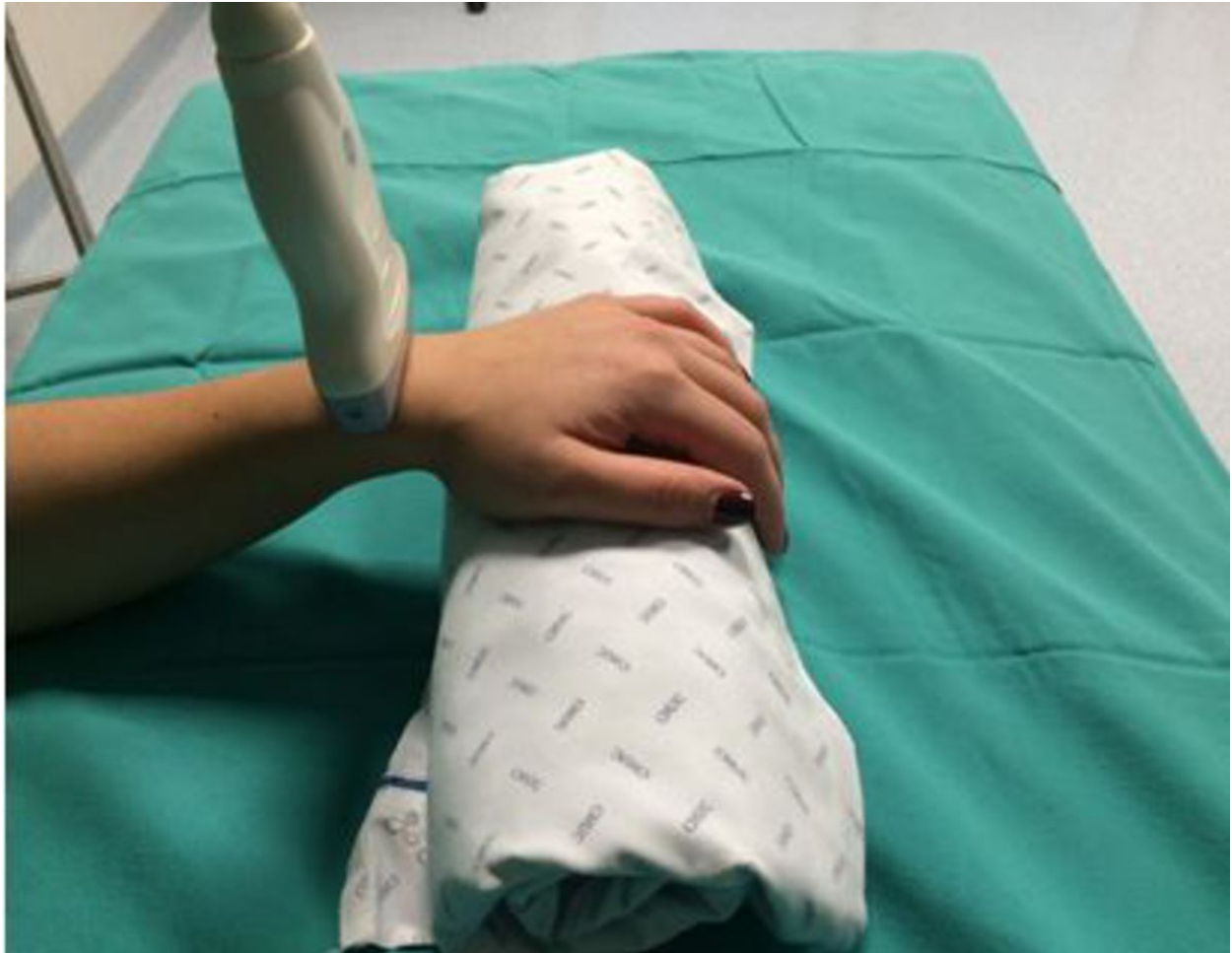

Fig. 2: Hand and transducer positioning.

© Radiology Department, Coimbra University Hospital - Coimbra/PT

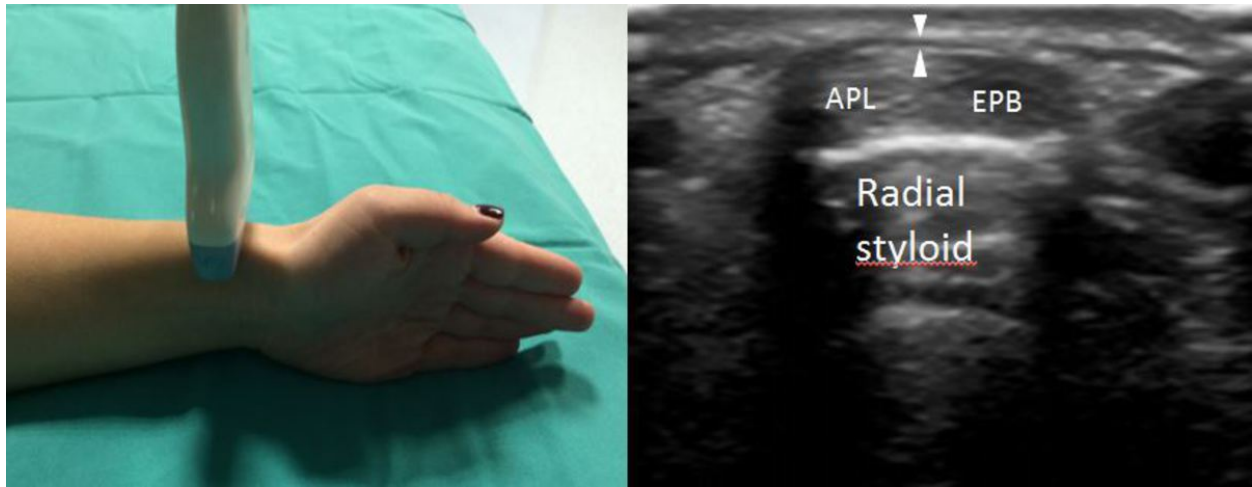


Fig. 3: First compartment. APL, abductor pollicis longus tendon; EPB, extensor pollicis brevis tendon; white arrowheads, retinaculum.

© Radiology Department, Coimbra University Hospital - Coimbra/PT

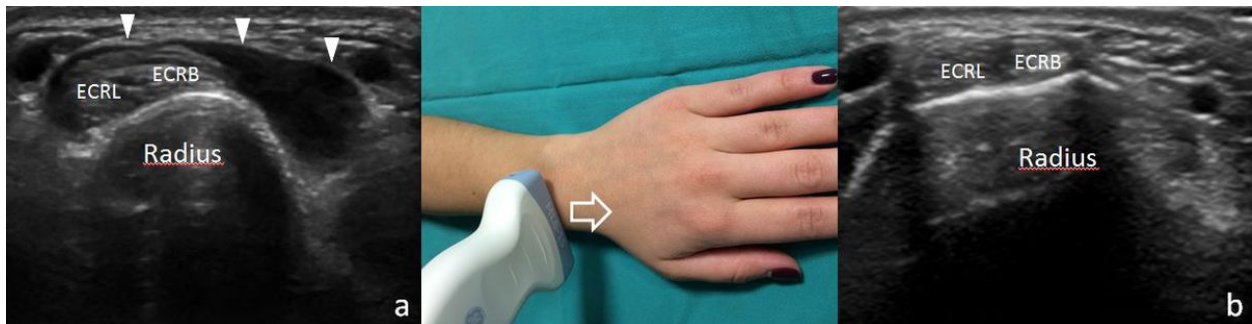


Fig. 4: a. Proximal and b. distal second compartment. ECRL, extensor carpi radialis longus tendon, ECRB, extensor carpi radialis brevis tendon; white arrowheads, tendons of the first compartment crossing superficial to the second compartment.

© Radiology Department, Coimbra University Hospital - Coimbra/PT

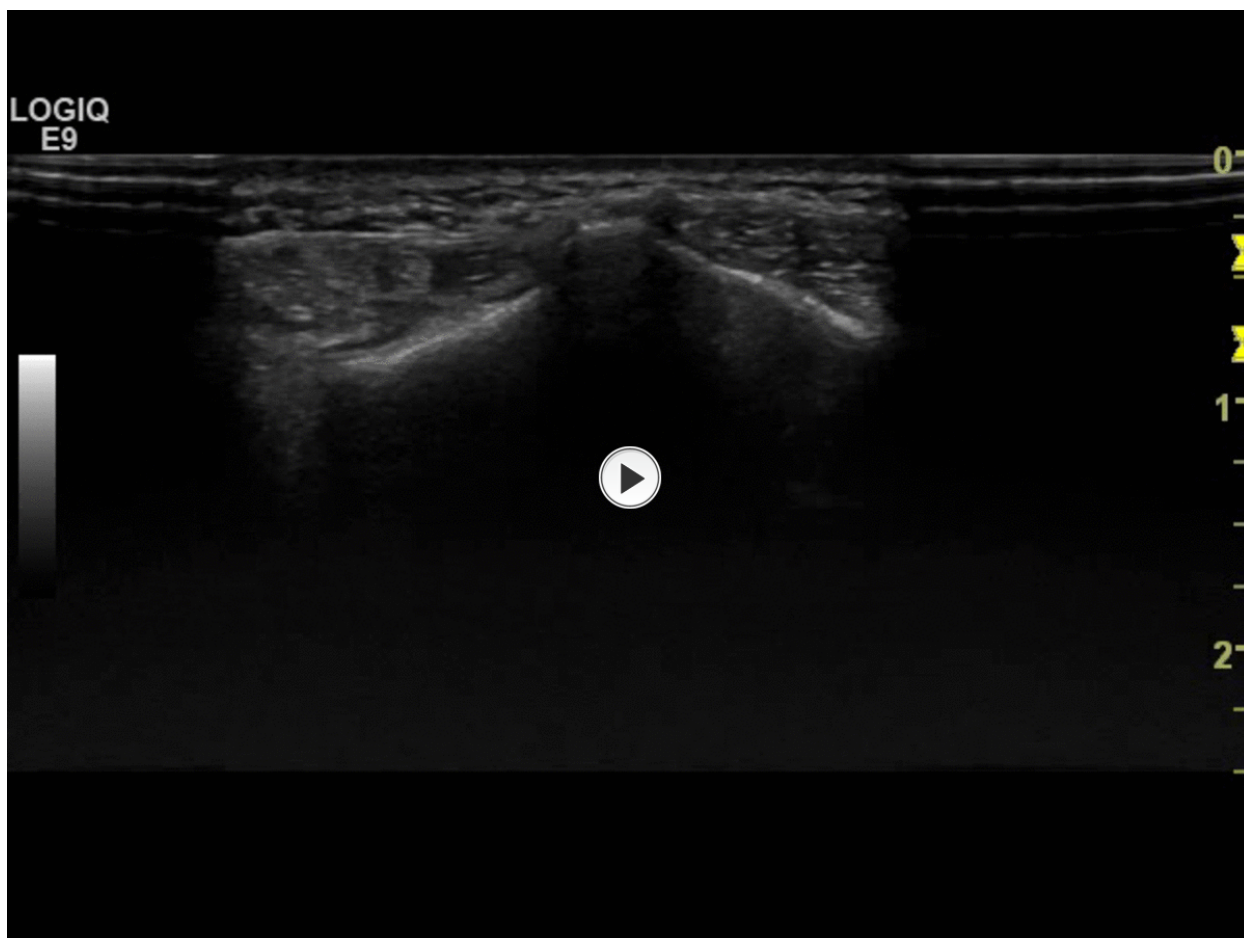


Fig. 5: Tendons of the first compartment crossing tendons of the second compartment superficially from the ulnar to the radial side.

© Radiology Department, Coimbra University Hospital - Coimbra/PT

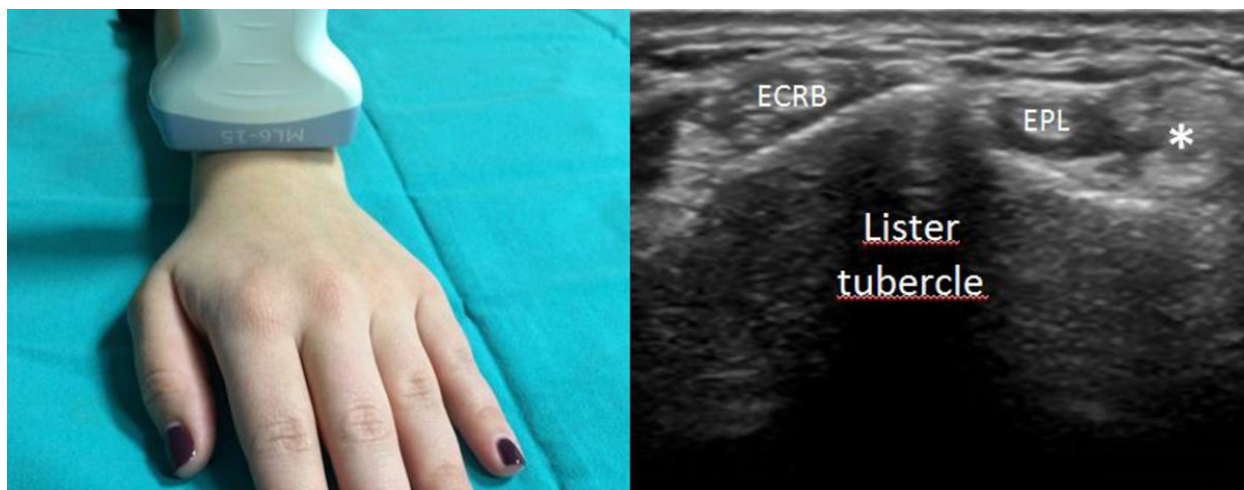


Fig. 6: Third compartment. ECRB, extensor carpi radialis brevis tendon; EPL, extensor pollicis longus tendon; asterisks, fourth compartment.

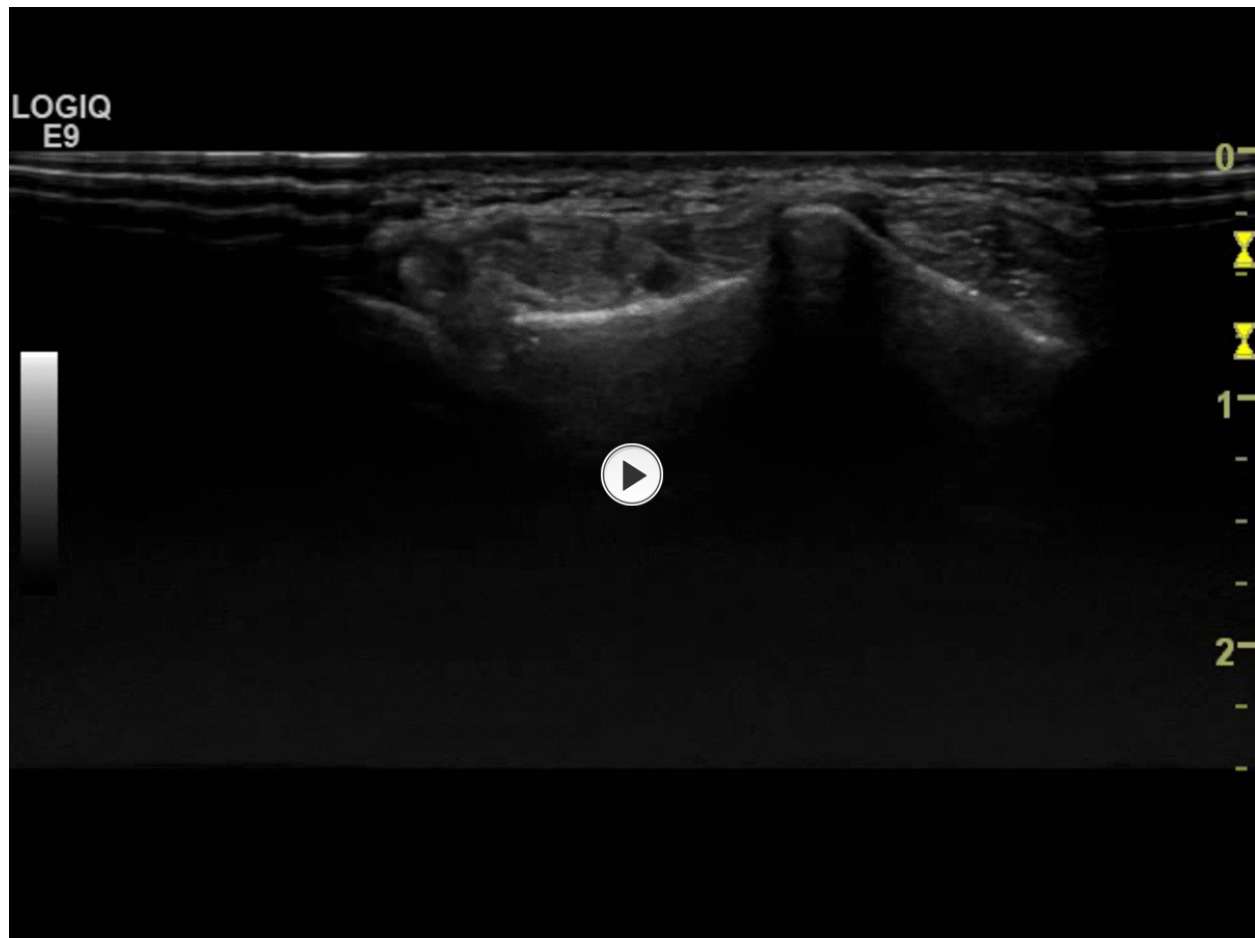


Fig. 7: EPL tendon crossing superficially the second compartment tendons.

© Radiology Department, Coimbra University Hospital - Coimbra/PT

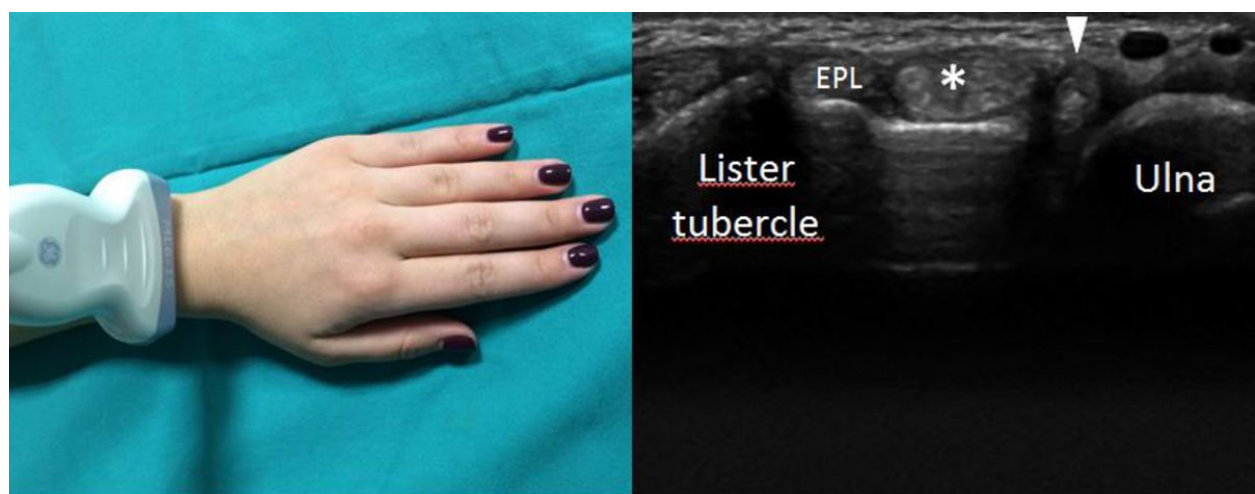


Fig. 8: Fourth and fifth compartments. ECRB, extensor carpi radialis brevis tendon; EPL, extensor pollicis longus tendon; asterisk, fourth compartment; arrowhead, extensor digiti minimi tendon.

© Radiology Department, Coimbra University Hospital - Coimbra/PT

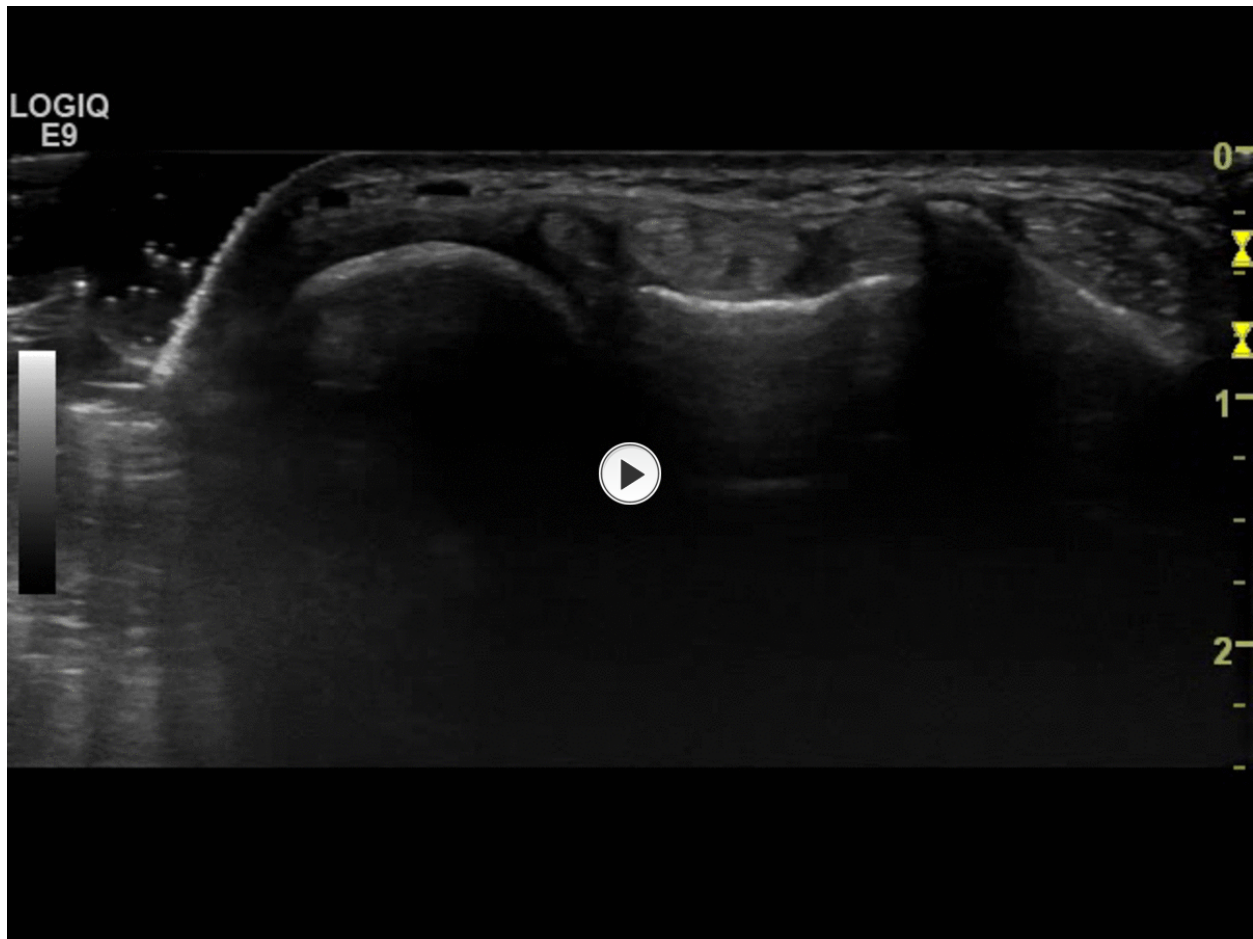


Fig. 9: Dynamic scanning of the fourth compartment.

© Radiology Department, Coimbra University Hospital - Coimbra/PT

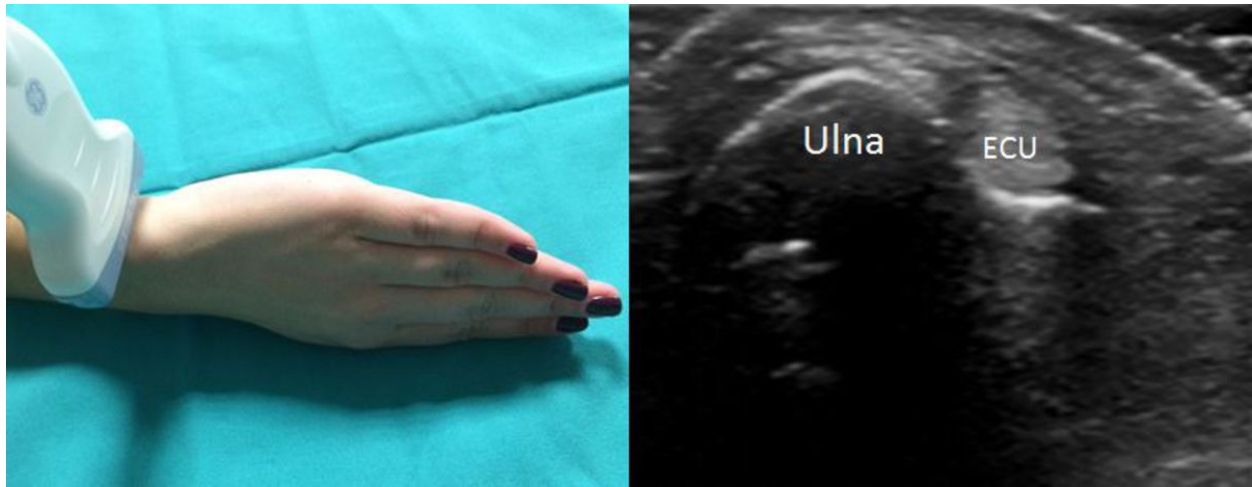


Fig. 10: Six compartment. ECU, extensor carpi ulnaris tendon.

© Radiology Department, Coimbra University Hospital - Coimbra/PT

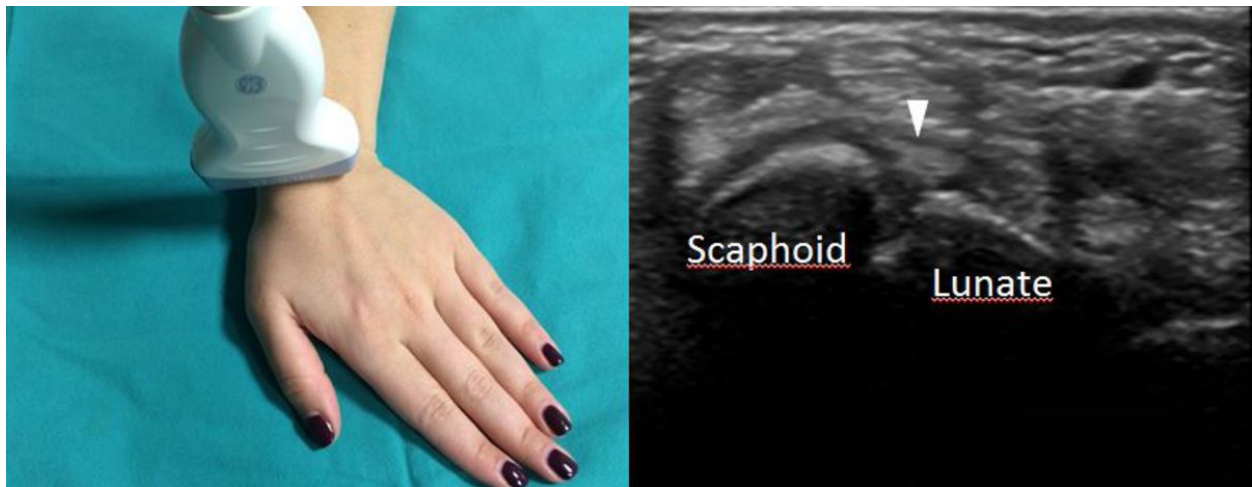


Fig. 11: Scapholunate ligament. White arrowhead, scapholunate ligament.

© Radiology Department, Coimbra University Hospital - Coimbra/PT

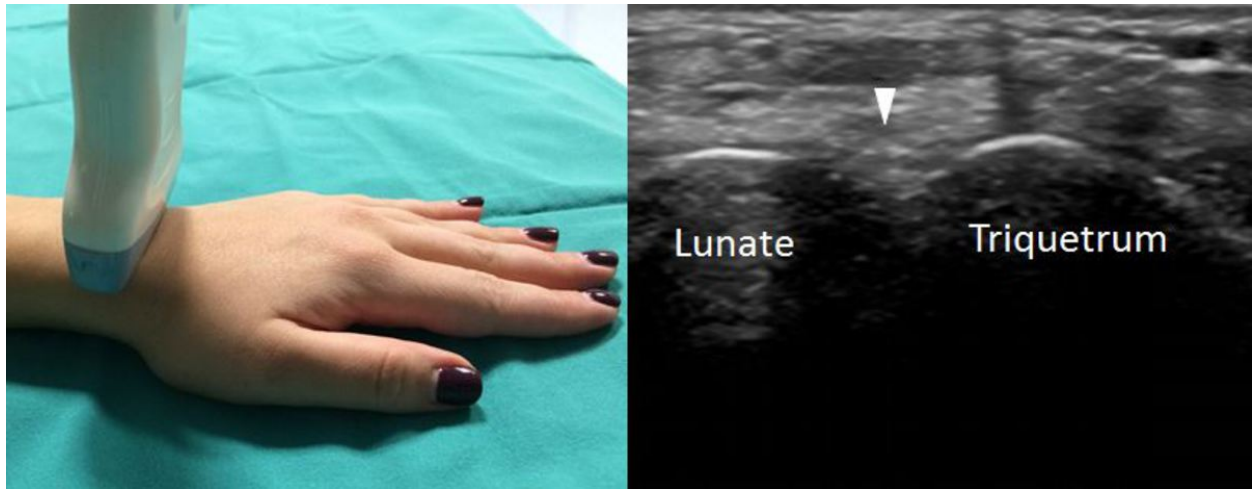

Fig. 12: Lunatutriquetral ligament. White arrowhead, lunatutriquetral ligament.

© Radiology Department, Coimbra University Hospital - Coimbra/PT

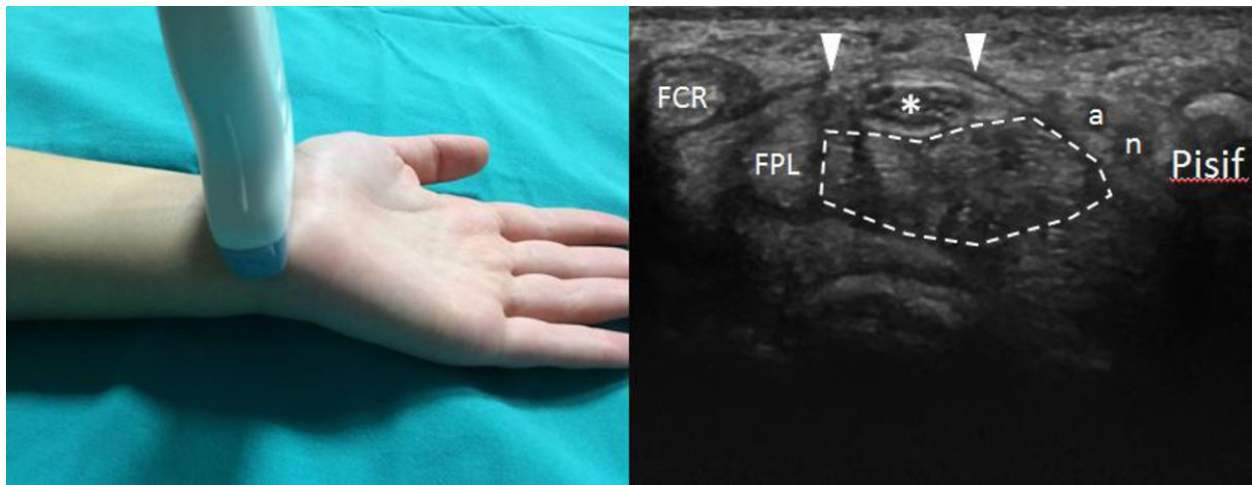


Fig. 13: Proximal carpal tunnel. FCR, flexor carpi radialis tendon; FPL, flexor pollicis longus tendon; asterisk, median nerve; white arrowheads, flexor retinaculum; inside white line, flexor digitorum profundus and superficialis tendons; a, ulnar artery; n, ulnar nerve; Pisif, pisiform.

© Radiology Department, Coimbra University Hospital - Coimbra/PT

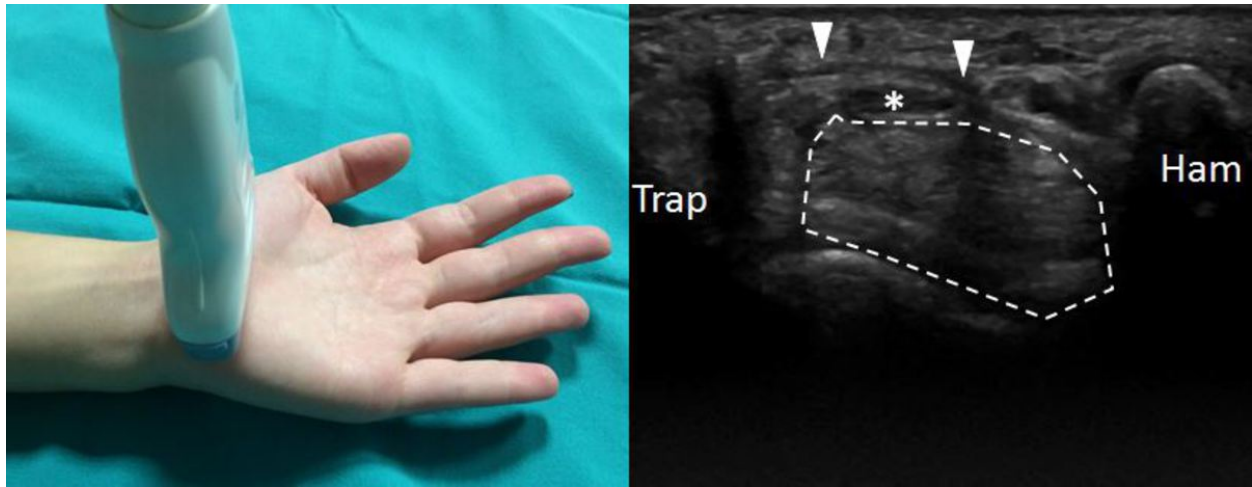


Fig. 14: Distal carpal tunnel. Trap, trapezium; asterisk, median nerve; white arrowheads, flexor retinaculum; inside white line, flexor digitorum profundus and superficialis tendons; ham, hamate.

© Radiology Department, Coimbra University Hospital - Coimbra/PT

Conclusion

Ultrasonography of the wrist provides dynamic and real-time evaluation of the integrity of the joint structures. Therefore the knowledge and the systematization of the wrist ultrasonography are essential, thus allowing diagnosis of frequent pathologies that are ultimately responsible for significant morbidity and functional disability.

Personal information

References

1. Beggs I, et al. Musculoskeletal ultrasound technical guidelines. III. Wrist. European Society of Musculoskeletal Radiology, 2006.
2. Bianchi S, Martinoli C. Wrist. Ultrasound of the musculoskeletal system. NewYork, NY: Springer, 2007.
3. Daniels, J. M. Wrist. Basics of musculoskeletal ultrasound. Springer, 2013.
4. Jacobson J.A. Fundamentals of musculoskeletal ultrasound. Philadelphia, Pa: Saunders Elsevier, 2007.
5. Justin C. L., et al. Normal sonographic anatomy of the wrist and hand. RadioGraphics 2005; 25: 1577-1590.